

# Levetiracetam and Speech Therapy in Aphasia from Penetrating Brain Injury. Could it be the Way To Recovery?

Z Ayyoub, R Ben-Youssef

Adult Brain Injury Service, Rancho Los Amigos National Rehabilitation Center, Downey, California

## Abstract

A previously healthy 26 years old right-handed man sustained a penetrating brain injury (PBI) from gunshot wound to the head. The bullet entered the right parieto-occipital junction, traveled diagonally through the occipital pole and ended in the left fronto-temporal lobe. He developed right hemiparesis and global aphasia. He was enrolled in speech therapy (ST), and was started on levetiracetam (LEV) 500 mg twice daily (BID) for seizure prophylaxis, then LEV was increased to 750mg BID. After 8 days on LEV 750 mg BID the patient pronounced the names of his children and answered questions appropriately with verbal "yes" and "no". At discharge, FIM scores in comprehension, expression, memory, and social interaction had all improved from 2 to 4. He was able to respond verbally at the 1-3 word level with 50% accuracy and had shown improvement in auditory comprehension and verbal expression. The patient was kept on LEV 750 mg BID for 7 months. He had 50 outpatient ST sessions. At 9 months, he was able to read

a paragraph he had written, and used a paper guide to scan lines. His comprehension of the written language improved to the sentence level, and his money management skills improved to modified independent. Conclusions: LEV appears to improve aphasia and cognitive outcomes of PBI patients treated with ST. Large prospective randomized trials are needed to confirm this clinical observation and to establish treatment protocols for PBI-induced aphasia that will incorporate ST and LEV.

**Key words:** Levetiracetam, aphasia, speech therapy, penetrating brain injury, rehabilitation.

## Introduction

Language and cognitive disorders are extremely common complications following stroke and traumatic brain injury. When they do not resolve, they become indicators for poor long-term functional outcome<sup>1-4</sup>. Acquired aphasia, apraxia of speech and dysarthria often result in significant disability and handicap<sup>4</sup>. Full recovery from aphasia is uncommon and limits patients' chances to live independently in the community or rejoin the workforce<sup>2-4</sup>.

Aphasia is marked by an impaired ability to comprehend or express language in its written or spoken form. General categories include receptive, expressive, and mixed or global aphasia. Aphasia affects about 1 in 250 Americans (more than one million). More than 100,000 Americans acquire the disorder each year. The majority of cases result from stroke, and the remainder are due to severe brain trauma, brain tumors, and neurodegenerative disease<sup>5</sup>. About 33% of surviving severe traumatic brain injury patients develop aphasia<sup>5</sup>. In the penetrating brain injury (PBI) population, this incidence ranges between 24% and 31%<sup>6</sup>.

Treatment for aphasia is controversial. Several published reports suggest that spontaneous biological recovery may explain most of the improvement in speech and verbal fluency seen in aphasics<sup>2,7-11</sup>. Here, we present the case of a patient with PBI induced global aphasia, and we discuss the improvement of his language and cognition after treatment with intensive speech therapy and adjunct pharmacotherapy with levetiracetam (LEV). To the best

## Authors and their affiliations

**Dr Ziyad Ayyoub, MD**, Chief Adult Brain Injury Service, Rancho Los Amigos National Rehabilitation Center, Downey, California, USA. Assistant Professor of PMR Loma Linda University, California, USA. Clinical Assistant Professor of PMR, Western University of Health Sciences, California, USA. Clinical Assistant Professor of Medicine, David Geffen School of Medicine at UCLA, California, USA.

**Dr Ramzi Ben-Youssef, MD**, Adult Brain Injury Service, Rancho Los Amigos National Rehabilitation Center, Downey, California. Department of PMR, Loma Linda University Medical Center, Loma Linda, California, USA.

## Bibliography

Ayyoub Z, Ben-Youssef R. Levetiracetam and Speech Therapy in Aphasia from Penetrating Brain Injury: Could It Be the Way To Recovery. IJPMR 2010; 21 (2): 51-55.

Article received: August 27, 2010.

## Correspondence

Dr Ziyad Ayyoub, MD  
7601 E. Imperial Highway  
Downey  
CA 90242  
USA

Email: zayyoub@dhs.lacounty.gov

of our knowledge, this is the first report about the impact of LEV on recovery from aphasia following PBI.

## Case Report

A previously healthy 26 years old right-handed Hispanic man sustained a civilian gunshot wound to the head. The bullet entered the right parieto-occipital junction, causing significant brain damage, and traveled diagonally through the occipital pole toward the frontal pole to become lodged in the left fronto-temporal lobe. He was initially intubated and treated with entrance wound debridement, continuous intracranial pressure monitoring and intravenous mannitol. He also was treated with intravenous antibiotics for acinetobacter pneumonia. The patient developed right hemiparesis, and impaired cognition, in addition to severe receptive and expressive aphasia. When he became stable for rehabilitation, he was admitted to our comprehensive rehabilitation center. As part of his treatment program, the patient received daily 1-hour sessions of speech and physical and occupational therapy 6 days a week, for 3 weeks. There was no evidence of seizure activity throughout the first 2 weeks after the PBI, and during the 21 days spent in the rehabilitation unit. However, in view of the patient's restlessness and agitation, an electroencephalogram (EEG) was performed. It demonstrated mild-to-moderate diffuse slowing of brain activity, more prominent in the left frontal lobe. Because of the penetrating nature of the brain injury, the patient was started on progressively increased dose of LEV for seizure prophylaxis. He initially received 500 mg twice daily (BID) by mouth for one week, which was well tolerated. Subsequently LEV was increased to 750 mg BID.

On examination, the patient was alert but unable to communicate in any modality, or to complete a review of systems. He had a right hemiparesis with a motor strength of 1-3/5 in the major muscle groups, worse in the upper extremity. A head computed tomography scan (CT) without contrast showed large bullet fragment with metallic artifact in the left fronto-temporal lobe, with edema surrounding the left periventricular region (Fig. 1A), in addition to an extended band-shaped hypodensity in the right postero-parietal region representing the bullet trajectory (Fig. 1B).

Review of patient's premorbid condition indicated he had 12 years of relatively successful education (11<sup>th</sup> grade of the US educational system) without any significant academic problems. However, he dropped out of school at the age of 16 to begin working in the construction field to support his family. He also has a history of illicit drug use, in addition to many years of alcohol abuse. He was married and had 2 children. His preferred language was English.

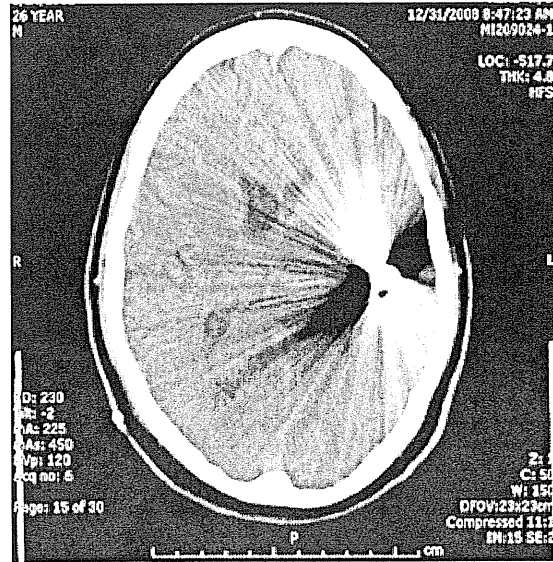


Fig 1A. Head computed tomography scan without contrast showing large bullet fragment with metallic artifact in the left fronto-temporal lobe with edema surrounding the left periventricular region.

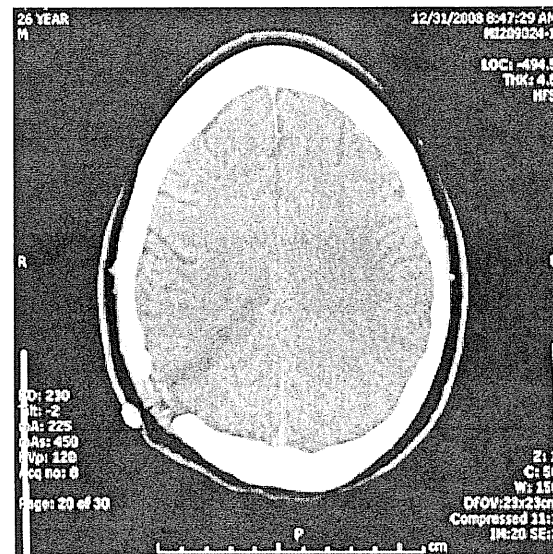


Fig 1B. Head computed tomography scan without contrast showing an extended band-shaped hypodensity in the right postero-parietal region representing the bullet trajectory.

During the first few days in rehabilitation, the patient was consistently aphasic and demonstrated minimal comprehension when asked about his strength, mood and general well-being. Initial functional independence measure (FIM) scores for comprehension were 2, indicating need for maximal assistance. For expression, memory and problem solving he had FIM scores of 1,

indicating need for total assistance. After 5 days on LEV 500 mg BID, the speech therapists noted that the patient was responding more accurately with head nodding and shaking, however he remained non-verbal. FIM scores for comprehension and social interaction remained at 2. However, 8 days after increasing the LEV dose to 750 mg BID, the patient began to say the names of his wife and children and started to answer questions appropriately with verbal "yes" and "no". He also showed improved accuracy with responses regarding his mood and general well-being, production of some simple words and increased smiling and laughing. FIM scores for comprehension and social interaction increased from 2 to 3. On his 9<sup>th</sup> day on LEV 750 mg BID, the patient accompanied his family and his therapists to a local park as part of the treatment program. Upon return he was able to verbalize that he "had a good time". Within 11 days of the increased dose of LEV, the patient was able to convey verbally that he wanted to resume sexual relations with his wife. At discharge from rehabilitation, the patient had been on LEV 750 mg BID for 14 days. At that point, his FIM scores in comprehension, expression, memory, and social interaction had all improved to a score of 4, indicating need for only minimal assistance. The patient demonstrated an ability to respond verbally at the 1-3 word level with approximately 50% accuracy and had shown steady improvement in auditory comprehension and verbal expression.

From a motor standpoint, the patient's initial FIM scores for locomotion and transfers were 2 and 3, respectively. They improved to 5 and 5 respectively at discharge, indicating only need for supervision or set-up for safety. The patient was able to ambulate at variable speeds, and demonstrated appropriate balance and equilibrium reactions. He was able to feed himself independently, and only needed setup and some verbal cues for hygiene and grooming and body dressing. The patient was discharged to his home with his wife and children, and was advised to continue taking LEV 750 mg twice daily.

Two weeks later, the patient scored 14/33 on the CASI-S mini-mental status exam, demonstrating problems with fluency, orientation and memory. Meanwhile, he was enrolled in outpatient speech therapy 2 times per week for a total of 50 sessions. At follow-up 9 months post-injury, the patient's memory, reading, and writing ability have improved significantly. As part of his therapy, he was able to read a paragraph he had previously written. He spontaneously used a paper guide to help him scan lines. His comprehension of the written language improved to the sentence level, and his money management skills improved to modified independent in functional settings.

## Discussion

Currently, the key treatment for aphasia is conventional speech and language therapy. However, the efficiency of this approach has not been decisively established and the need for additional treatment options is there<sup>2, 7-13</sup>. Pharmacotherapy of aphasia had been discussed for the last two decades. However, of all the products used, only a few drugs like piracetam, donepezil, and amphetamine have shown some limited efficacy<sup>2, 3, 7, 12-16</sup>.

On the other hand, 30% to 50 % of patients with PBI develop seizures. Of those, 4-10 % develop the seizure during the first week after injury, 80% within the first 2 years, and about 18% will only have seizures after 5 years post injury or later<sup>17, 18, 19</sup>. Seizure activity in the early post-traumatic period following head injury may cause secondary brain damage as a result of increased metabolic demands, raised intracranial pressure and excess neurotransmitter release<sup>20</sup>. It is therefore imperative for patients suffering from PBI to receive early seizure prophylaxis with drugs such as phenobarbital, valproate or with the newer product LEV<sup>20, 21, 22</sup>.

Levetiracetam is an S-enantiomer which derives from piracetam. Both are cyclic pyrrolidone products that derive from gamma-aminobutyric acid. LEV was initially studied in animal models of cognitive impairment with the primary objective of finding a drug more effective than piracetam. However LEV was initially considered to be more effective in preventing seizures<sup>23</sup>. Investigations into the effect of LEV on fluency and cognition have been performed in several studies, all of which focused on patients with an established diagnosis of epilepsy. Most comprehensively studied by Piazzini et al<sup>24</sup> 70 patients with diagnosed partial epilepsy were divided into two groups of 35 patients. Both groups underwent a battery of neuropsychological tests twice, at a 7 week interval, with one group testing before and after receiving 7 weeks of a therapeutic dose of LEV. The LEV group demonstrated improved cognitive function and oral fluency which did not correlate with seizure frequency. This observation has led to the hypothesis that the antiepileptic mechanism of LEV is distinct from its effect on speech and attention. It has been suggested that LEV may have an influence on the brain's metabolism in areas devoted to attention and language similar to what has been suggested with piracetam, the other pyrrolidone derivative found to be associated with improved learning, memory and attention. In fact, there is some evidence that piracetam enhances glucose utilization and cellular metabolism in the brain<sup>15, 24</sup>. Sechi and colleagues<sup>25</sup> prospectively examined the effects of LEV on 5 patients with partial epilepsy and disfluent speech and found that verbal fluency and speed of oral reading improved but

also found that seizure frequency did not correlate with this improvement. Furthermore, Hannon<sup>26</sup> had suggested LEV appears to possess newer properties which differentiate it from older anticonvulsant drugs. He speculated LEV may prevent extensive neuronal loss and associated axonal reorganization, known as fiber sprouting, which is thought to be epileptogenic and lead to additional neuronal death. Therefore, LEV seems to play a dual neuroprotective role, probably relevant to its anticonvulsant and antiepileptogenic action. This role is similar to that of conventional antiepileptic drugs like phenobarbital and valproate; however it comes with less frequent and less severe side effects<sup>27</sup>. Additionally, LEV does not require titration or drug level monitoring and it has demonstrated rapid onset of action<sup>28</sup>.

The long-term effect of LEV on cognition and quality of life was examined by Lopez-Gongora et al<sup>29</sup>. Twenty-seven epileptic patients were found to have improved memory, verbal fluency and quality of life at one year on 2000 mg of LEV daily. Our patient was initially started on LEV for seizure prophylaxis and not with the intention to treat his aphasia. However our clinical observation suggested an improvement in patient motor speech, fluency, and cognition after starting him on LEV, and more precisely after increasing the dose to 750 mg BID (about 22 mg/kg of patient's 70 kg body weight). At present, the guidelines for management of PBI do not recommend prophylaxis of late post-PBI epilepsy<sup>30</sup>, however in view of the considerable improvement observed of our patient's aphasia and cognitive function, which was thought to be due in part to LEV, we kept the patient on LEV during the whole length of the outpatient treatment program; about 7 months. The idea of dose-effect correlation of LEV and piracetam has been previously described in animal studies<sup>23</sup>. In fact, while piracetam improved the learning and memory of the studied mice at 10 mg/kg, LEV was only effective at higher doses (17-54 mg/kg). However, prospective research is needed to characterize this relationship in more detail and to establish disease-specific therapeutic ranges.

Finally, the excellent functional outcome of our patient could be due in part to the limited extent of cerebral injury and to the limited total brain volume loss from the low velocity civilian missile, as shown on the CT scan images (Fig 1A, B), and as reflected on the EEG results, which did not show any anterior temporal or central spike foci, or any significant focal slowing. The latter anomalies are more frequently seen in war casualties from very high velocity military ammunition, and are almost always associated with more severe brain damage, post PBI seizures, Broca's aphasia, and focal neurologic deficits, in addition to rare motor and cognitive recovery rates<sup>31</sup>. The type of diffuse EEG slowing that was seen in our

patient is very common in the first few weeks after PBI, and its incidence usually drops rapidly within the next six months following the injury<sup>31</sup>.

## Conclusion

While LEV was shown to improve the cognition and fluency of epileptic patients, LEV also appears to improve aphasia and cognitive outcomes of PBI patients treated with intensive speech therapy. Whether this effect is the result of metabolic changes in the injured brain tissue, and whether this role depends on the dose of LEV used, is beyond the scope of this report. However, large prospective randomized trials are needed to confirm this clinical observation, and to establish treatment protocols for PBI induced aphasia that will incorporate intensive speech therapy and LEV.

## References

1. Ludlow CL, Rosenberg J, Fair C, Buck D, Schesselman S, Salazar A. Brain lesions associated with nonfluent aphasia fifteen years following penetrating head injury. *Brain* 1986; 109 (Pt 1): 55-80.
2. Bakheit AM. Drug treatment of poststroke aphasia. *Expert Rev Neurother*. 2004; 4: 211-7.
3. Liepert J. Pharmacotherapy in restorative neurology. *Curr Opin Neurol*. 2008, 21: 639-43.
4. Jordan LC, Hillis AE. Disorders of speech and language: aphasia, apraxia and dysarthria. *Curr Opin Neurol*. 2006; 19: 580-5.
5. National Aphasia Association. More about aphasia. 2000. Available from: [http://www.aphasia.org/Aphasia%20Facts/aphasia\\_facts.html](http://www.aphasia.org/Aphasia%20Facts/aphasia_facts.html)
6. Mohr JP, Weiss GH, Caveness WF et al. Language and motor disorders after penetrating head injury in Vietnam. *Neurology* 1980; 30: 1273-9.
7. de Boissezon X, Peran P, de Boysson C, Démonet JF. Pharmacotherapy of aphasia: myth or reality? *Brain Lang*. 2007; 102: 114-25.
8. Greener J, Enderby P, Whurr R. Speech and language therapy for aphasia following stroke. *Cochrane Database Syst Rev*. 2000: CD000425. Review.
9. Holland AL, Fromm DS, DeRuyter F, Stein M. Treatment efficacy: aphasia. *J Speech Hear Res*. 1996; 39: S27-36.
10. Parton A, Coulthard E, Husain M. Neuropharmacological modulation of cognitive deficits after brain damage. *Curr Opin Neurol*. 2005; 18: 675-80.
11. Dobkin BH. Clinical practice. Rehabilitation after stroke. *N Engl J Med*. 2005; 352: 1677-84.
12. Ferro JM, Mariano G, Madureira S. Recovery from aphasia and neglect. *Cerebrovasc Dis*. 1999; 9 Suppl 5: 6-22.
13. Kessler J, Thiel A, Karbe H, Heiss WD. Piracetam improves activated blood flow and facilitates rehabilitation of poststroke aphasic patients. *Stroke* 2000; 31: 2112-6.

14. Walker-Batson D, Curtis S, Natarajan R, et al. A double-blind, placebo-controlled study of the use of amphetamine in the treatment of aphasia. *Stroke* 2001; 32: 2093-8.
15. Paola Canevini M, Chifari R, Piazzini A. Improvement of a patient with stuttering on levetiracetam. *Neurology* 2002; 59: 1288.
16. Huber W, Willmes K, Poeck K, Van Vleymen B, Deberdt W. Piracetam as an adjuvant to language therapy for aphasia: a randomized double-blind placebo-controlled pilot study. *Arch Phys Med Rehabil.* 1997; 78: 245-50.
17. Caveness WF, Meirowsky AM, Rish BL, et al. The nature of posttraumatic epilepsy. *J Neurosurg.* 1979; 50: 545-53.
18. Salazar AM, Jabbari B, Vance SC, Grafman J, Amin D, Dillon JD. Epilepsy after penetrating head injury. I. Clinical correlates: a report of the Vietnam Head Injury Study. *Neurology* 1985; 35: 1406-14.
19. Aarabi B. Management of missile head wounds. *Neurosurgery Quart.* 2003; 13: 87-104.
20. Schierhout, Gillian. Anti-epileptic drugs for preventing seizures following acute traumatic brain injury [Intervention Review]. *Cochrane Database of Systemic Reviews.* 2001: CD000173.
21. Chang BS, Lowenstein DH: Quality Standards Subcommittee of the American Academy of Neurology. Practice parameter: antiepileptic drug prophylaxis in severe traumatic brain injury: report of the Quality Standards Subcommittee of the American Academy of Neurology. *Neurology* 2003; 60: 10-16.
22. Jones KE, Puccio AM, Harshman KJ, et al. Levetiracetam versus phenytoin for seizure prophylaxis in severe traumatic brain injury. *Neurosurg Focus.* 2008; 25: E3.
23. Genton P, Van Vleymen B. Piracetam and levetiracetam: close structural similarities but different pharmacological and clinical profiles. *Epileptic Disord.* 2000; 2: 99-105.
24. Piazzini A, Chifari R, Canevini MP, Turner K, Fontana SP, Canger R. Levetiracetam: an improvement of attention and of oral fluency in patients with partial epilepsy. *Epilepsy Res.* 2006; 68: 181-8.
25. Sechi G, Cocco G, D'Onofrio M., Deriu M., Giulio R. Disfluent speech in patients with partial epilepsy: Beneficial effects of levetiracetam. *Epilepsy and Behavior.* 2006; 9: 521-523.
26. Hanon E, Klitgaard H. Neuroprotective properties of the novel antiepileptic drug levetiracetam in the rat middle cerebral artery occlusion model of focal cerebral ischemia. *Seizure* 2001; 10: 287-93.
27. Nicolson A, Lewis SA, Smith DF. A prospective analysis of the outcome of levetiracetam in clinical practice. *Neurology* 2004; 63: 568-70.
28. French J, Arrigo C. Rapid onset of action of levetiracetam in refractory epilepsy patients. *Epilepsia* 2005; 46: 324-6.
29. Lopez-Gongora M., Martinez-Domeno A., Garcia C., Escartin A. Effect of levetiracetam on cognitive functions and quality of life: a one-year follow-up study. *Epileptic Disorders* 2008; 10: 297-305.
30. Antiseizure prophylaxis for penetrating brain injury. *J Trauma.* 2001; 51: S41-S43.
31. Jabbari B, Vengrow MI, Salazar AM, Harper MG, Smutok MA, Amin D. Clinical and radiological correlates of EEG in the late phase of head injury: a study of 515 Vietnam veterans. *Electroencephalogr Clin Neurophysiol.* 1986; 64: 285-93.